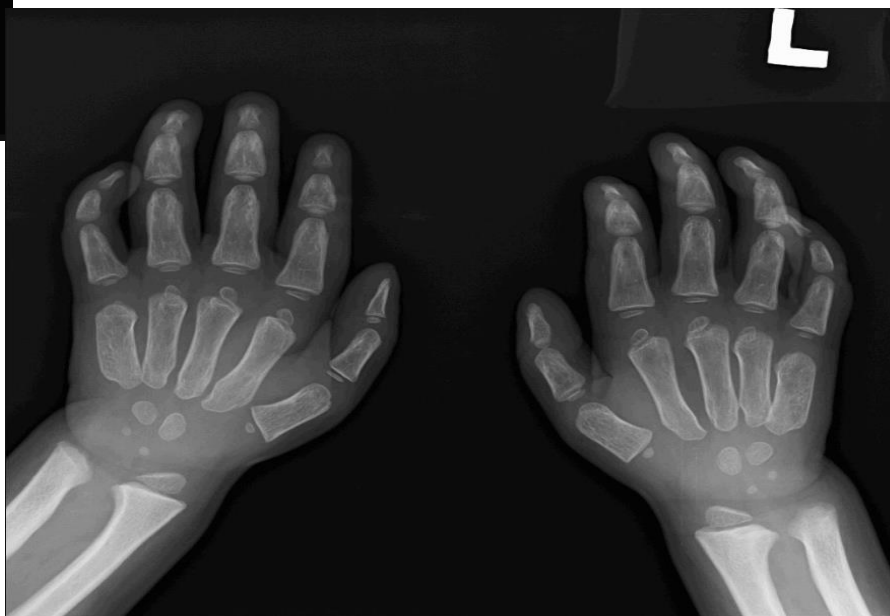
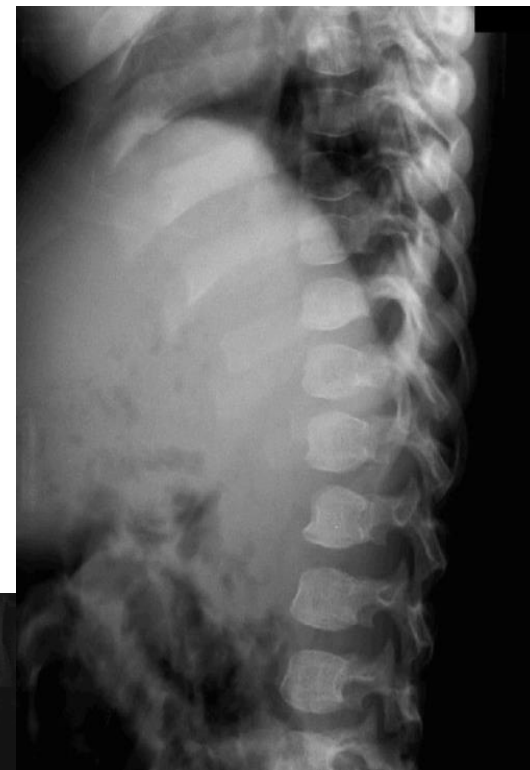
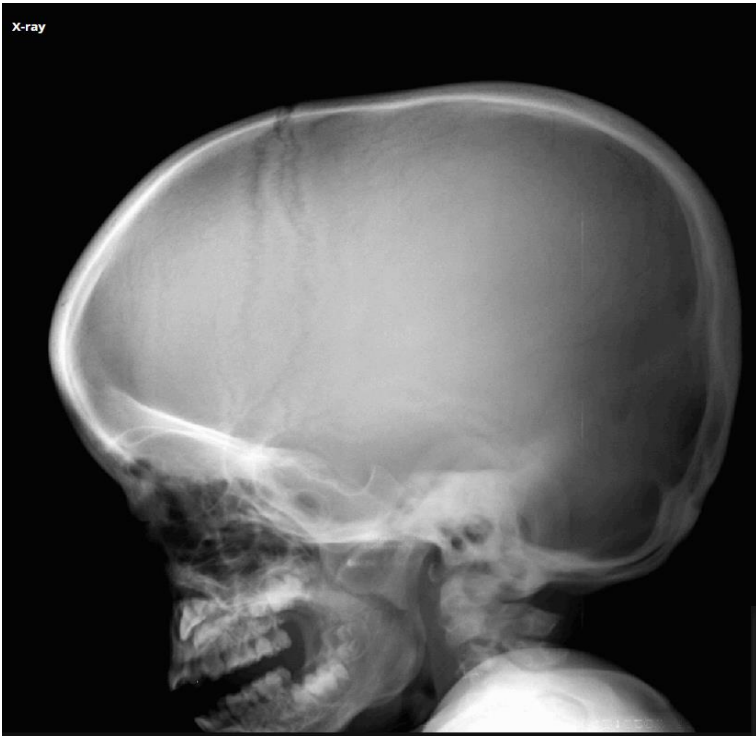


2025

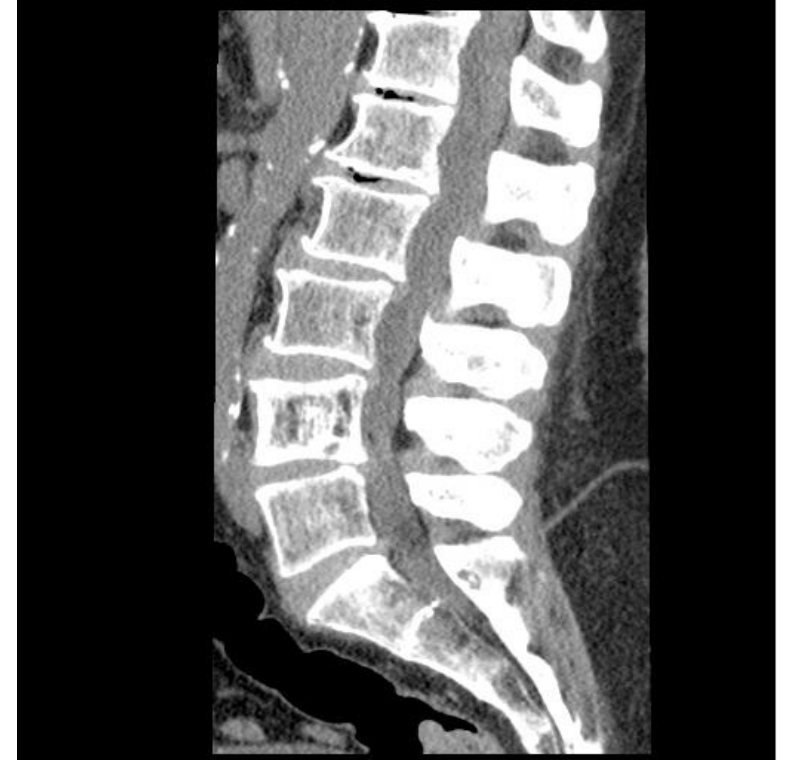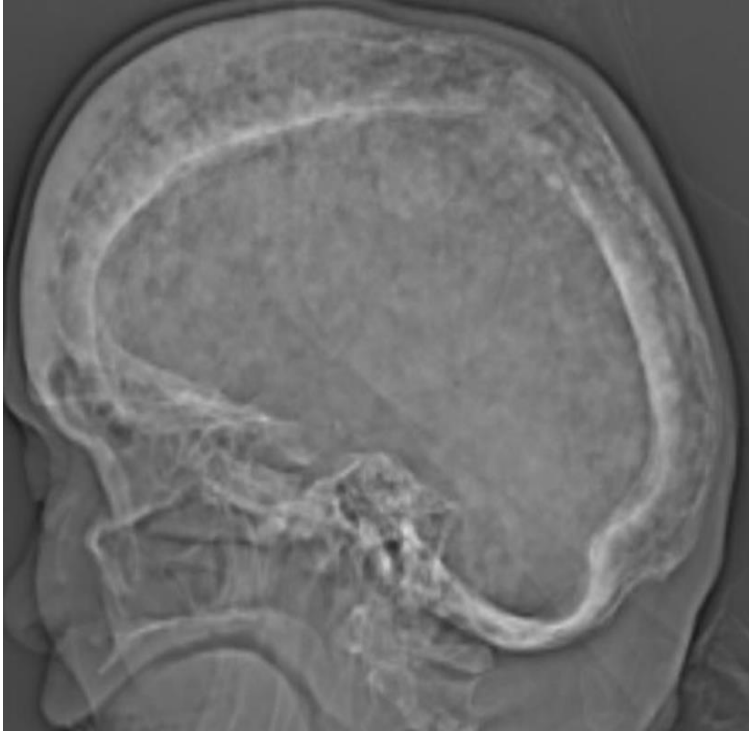
KARNATAKA RADIOLOGY EDUCATION PROGRAM

SPOTTERS



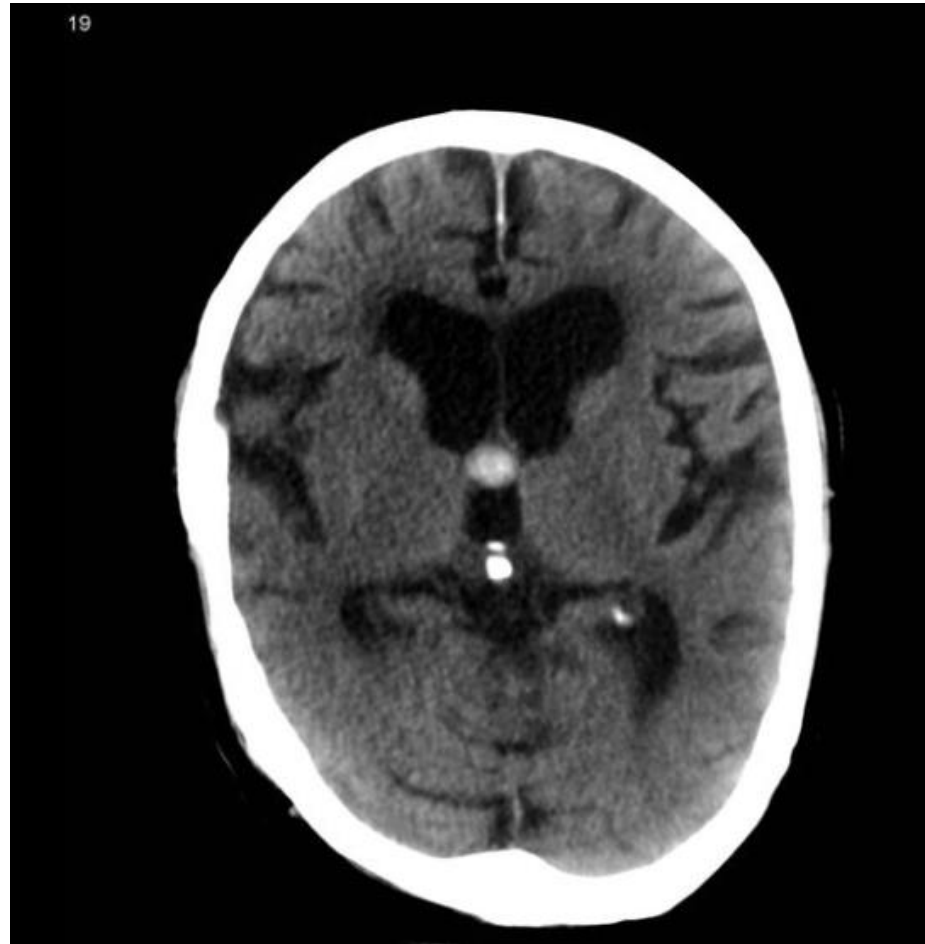MUCOPOLYSACCHARIDOSES

1. Macrocephaly
2. J shaped sella
3. Proximal pointing of metacarpals
4. Anterior beaking of inferior endplates



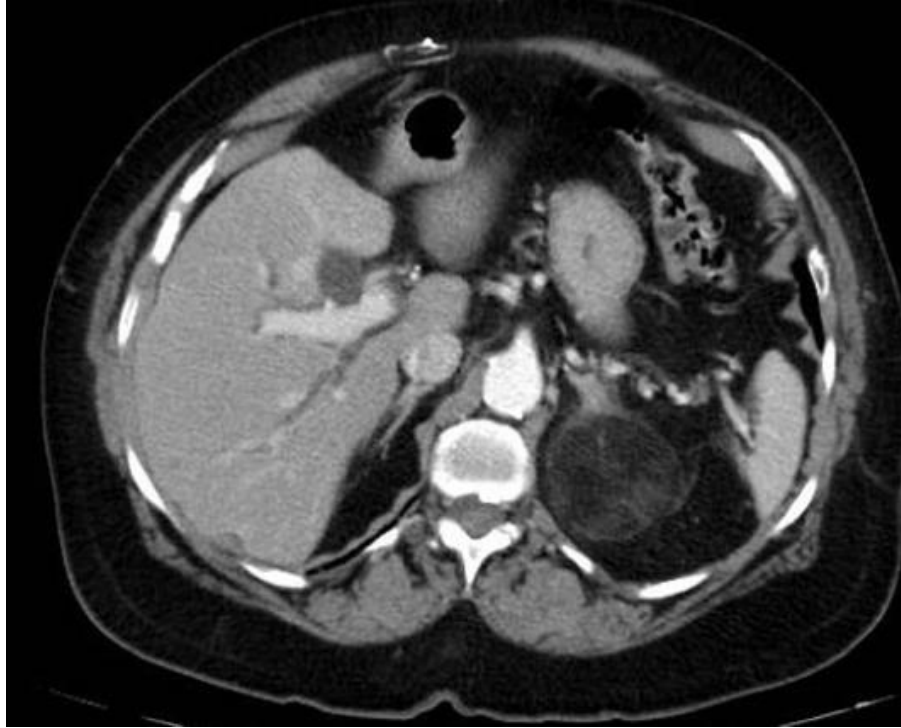
PAGET'S DISEASE

- Widening of diploic space
- Cotton wool appearance of the skull
- Picture frame vertebral body -increased opacity of the cortex on all sides of the vertebral body.



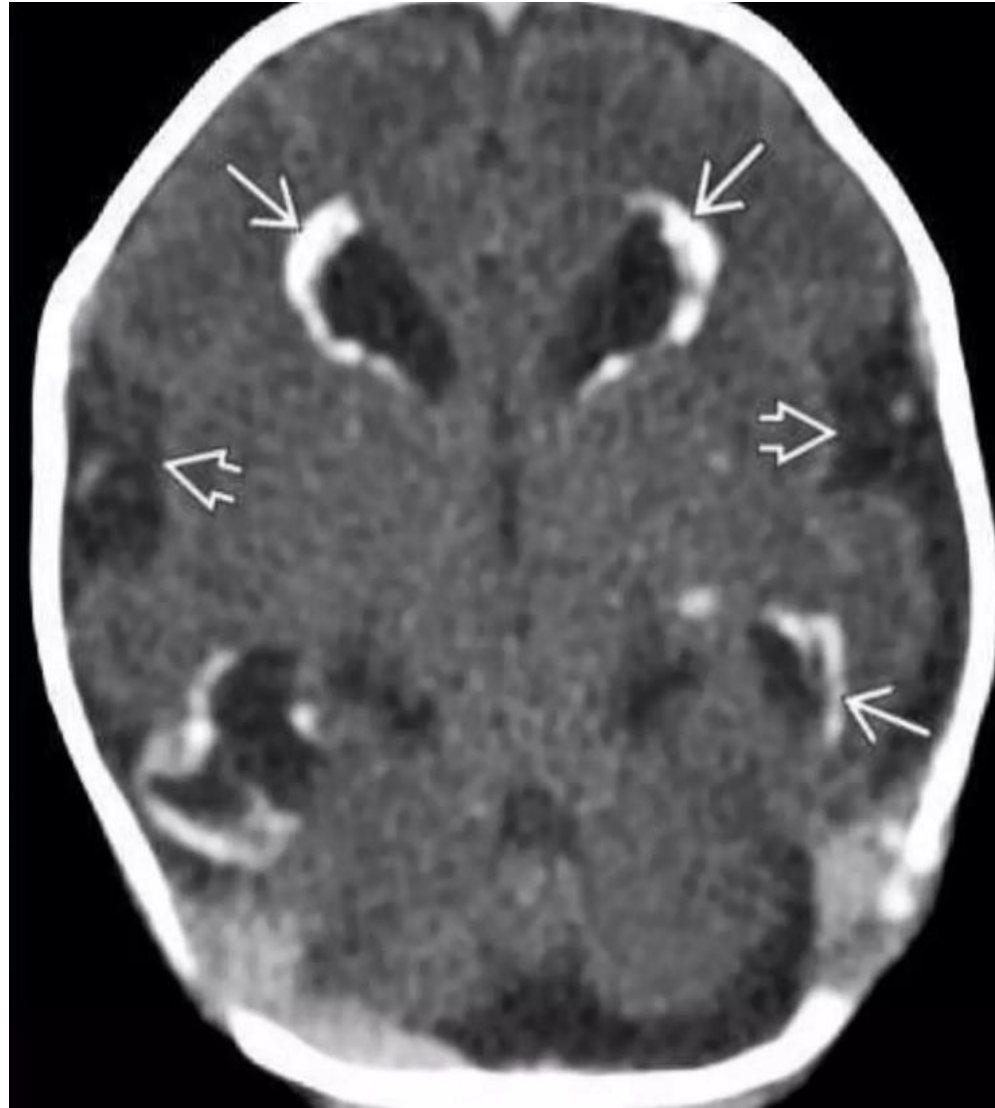COLLOID CYST

- Rounded hyperdense mass at the level of the foramen of Monro



Adrenal myelolipoma

- Well-circumscribed left adrenal mass with fat attenuation



Congenital cytomegalovirus infection

- NECT showing intracranial calcifications, predominantly peri-ventricular.